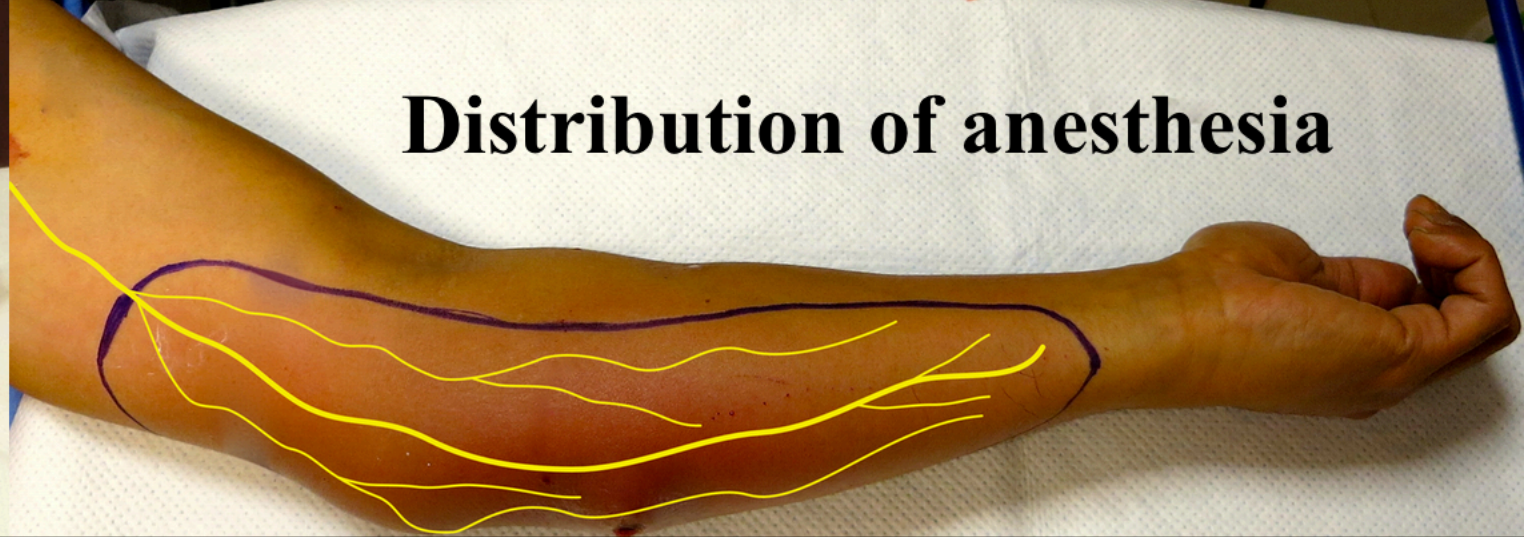
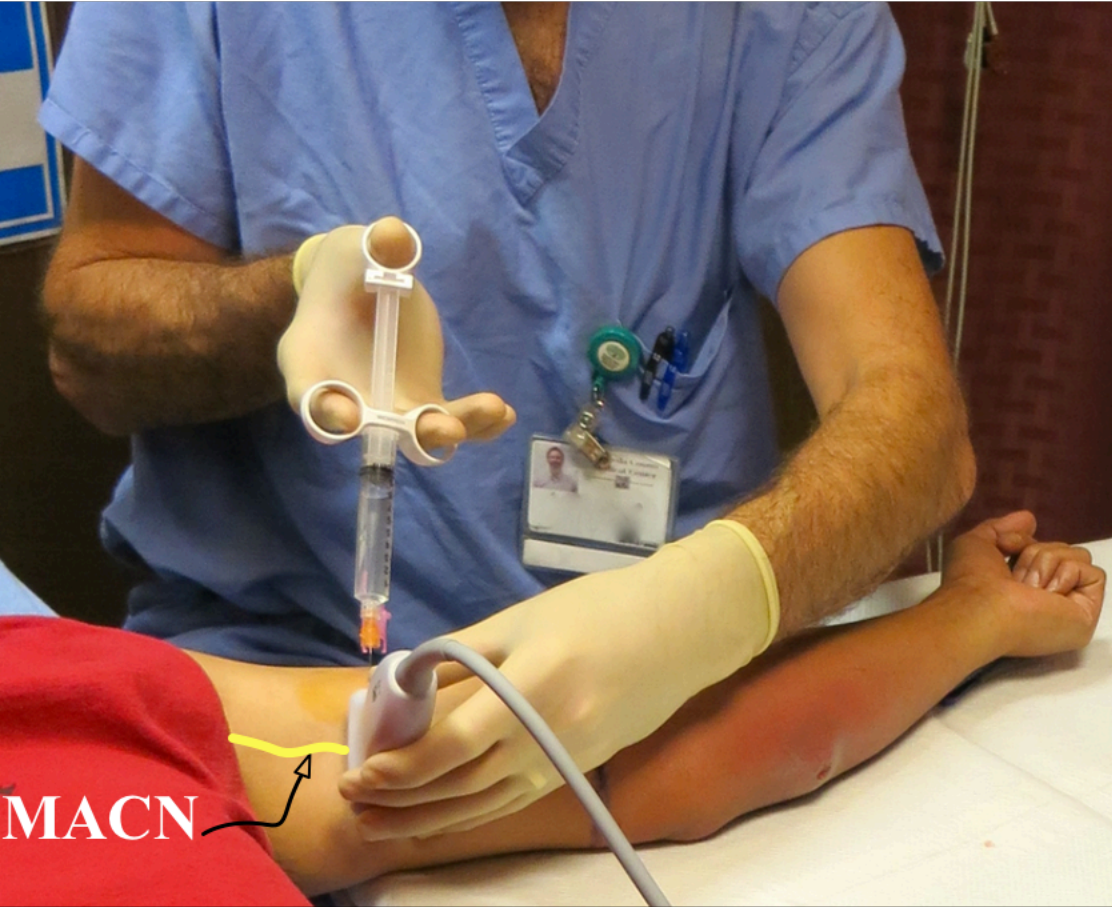
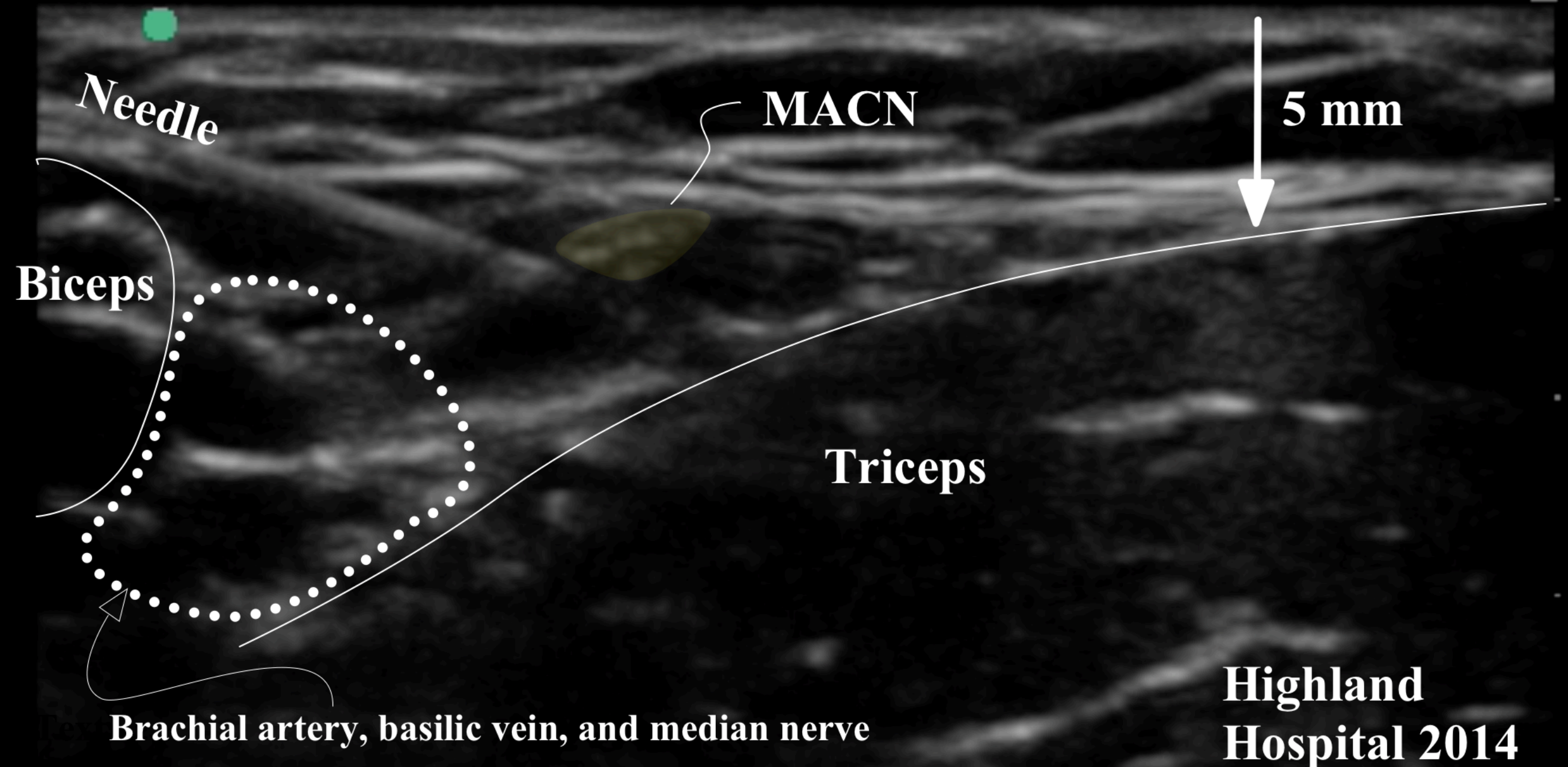


The medial antebrachial cutaneous nerve (MACN)
Scan medial aspect, mid-arm, identify biceps, triceps,
and the brachial artery/basilic vein/median nerve
complex. The MACN is quite superficial with a
typical honeycomb appearance.



Distribution of anesthesia

MACN



Needle

MACN

5 mm

Biceps

Triceps

Brachial artery, basilic vein, and median nerve

Highland
Hospital 2014